

DERMATOLOGICAL IMPLICATIONS OF SKELETAL AGING: A FOCUS ON SUPRAPERIOSTEAL VOLUMIZATION FOR PERIORAL REJUVENATION

Danny Vleggaar MD,^a Rebecca Fitzgerald MD^b

a. Le Col, Les Escombes, Roussas France

b. University of California Los Angeles, Los Angeles, CA

Abstract

It is becoming widely accepted that volume changes in the skin and soft tissue contribute greatly to age-related facial reshaping. A significant contribution to these volume changes is the loss of craniofacial skeletal support to the overlying soft tissue. Gravity, once considered the major culprit in facial aging, is now recognized to determine the direction, rather than the extent, of tissue deflation. Although the sequence of events observed in aging is somewhat predictable, its pace among individuals is variable and may be influenced by both intrinsic (eg, gender, genetics) and extrinsic (eg, photoaging, smoking, stress) factors. Changes in different tissue layers within a single individual do not occur independently, but interdependently; changes in one tissue within an individual may influence subsequent changes in other tissues. Midfacial soft tissue descent has been observed in response to decreased craniofacial support in both congenital craniofacial hypoplasia and following trauma, leading to a hypothesis that the loss of underlying bony support for any reason, including aging, leads to soft tissue descent in the face. As craniofacial support (the “table”) decreases, it leaves less surface area for the outer soft tissue envelope (the “tablecloth”) causing it to fold or sag. Replacing this deep support with craniofacial implants has been shown to reposition the overlying soft tissue. Following a brief review of the current literature on aging changes in the skin, soft tissue, and bone; the authors describe their experience with the use of poly-L-lactic acid (PLLA), both as a soft tissue volumizer and as an injectable craniofacial implant in a supraperiosteal location to address both soft tissue volume loss and loss of craniofacial support. In the cases presented, the most striking result noted was the ability to restore a youthful proportion to the perioral area, which had not been achieved previously with soft tissue treatment alone.

Introduction

Facial beauty and attractiveness are important cross-cultural social concepts as they tend to dictate how individuals are judged and treated.¹ Research has shown that facial beauty is perceived and processed rapidly by the brain and this perception biases subsequent cognitive processes.² A recent extensive review of research on facial beauty determined that 4 characteristics emerge as the most important determinants of attractiveness: averageness (prototypicality), sexual dimorphism, youthfulness, and symmetry.³

As the population continues to age and cosmetic procedures gain more acceptance, adults from all age groups and socioeconomic backgrounds are seeking cosmetic improvement. The majority of patients seeking cosmetic treatment are females 35 to 50 years old; however, the demand is increasing in both older and younger patients, as well as in men. The demand for cosmetic procedures in patients aged 51 to 65 years has doubled in the last 5 years.⁴ In December 2006, the Harris Group conducted a survey commissioned by the American Society of Plastic Surgeons. They interviewed 800 American women who reported that they were at least somewhat likely to have a medical antiaging treatment in the next 2 years. Results showed that the respondents clearly chose an injectable treatment over surgery and wanted a natural-looking and refreshed appearance with a reasonable duration that made them look about 10 years younger. These

results are reflected in recent statistics by the American Society for Aesthetic Plastic Surgery, which show that 83% of the 11.5 million rejuvenation procedures performed in 2006 were nonsurgical, with botulinum toxin and fillers leading the list.⁴

The current understanding that volume loss contributes much to the appearance of the face as we age in combination with the advent of newer products and techniques has dramatically increased the ability to address these changes outside of the operating room. Volume replacement, although not a substitute for conventional surgery, may delay or enhance cosmetic surgical procedures. In addition, as understanding the location of volume loss and optimal targets for replacement improves, so do results.

This article briefly reviews some of the newer literature concerning structural changes in different facial tissue layers including skin, fat, muscle, and bone. Next, the authors present a short discussion of the morphologic manifestations seen following these changes, including alterations in contours and topography of the face and changes in facial proportions associated with aging. Several case studies will illustrate the effects of treatments with poly-L-lactic acid (PLLA) injected into the soft tissue and in a supraperiosteal location to restore both youthful contours and proportions (specifically in the perioral region) to the aging face.

Volume Loss and Structural Changes in Multiple Tissue Layers

Skin

The skin thins with age, with the overall skin thickness decreasing significantly in a linear fashion after age 20.⁵ It is thought that reduced collagen in the dermis is responsible for the gradual loss in thickness, as collagen is the major determinant of skin thickness.⁶ In addition, a loss of the organization of elastic fibers occurs. Other histologic changes include flattening of the rete pegs with subsequent effacement of the dermal-epidermal junction.⁷ The epidermal architecture becomes progressively chaotic and the dermal vasculature dilates. Clinically, the skin subsequently appears thinner, drier, and less elastic, and begins to wrinkle and sag. These textural changes are accompanied by color changes as areas of hypopigmentation, hyperpigmentation, and visible vessels appear. The addition of extrinsic factors such as solar radiation, and perhaps smoking, greatly exacerbate these changes.⁷

The result of these changes is an outer skin envelope of the face that is less able to completely accommodate any underlying volume loss or shift, thus causing the skin to fold or sag. Consider a newly inflated balloon—if it is deflated quickly, it reassumes almost its original size; however, if it is deflated very slowly over time, it will not. Indeed, in faces with minimal underlying volume loss and shift, simply tightening the skin alone (via surgical lift, a deep peel, or a laser or light-tightening device) improves the overall appearance. Retinoids and sunscreens have traditionally been the biggest defense against many extrinsic insults, and effective topicals such as antioxidants and DNA repair creams add to this armamentarium. New and innovative treatments are constantly evolving.⁸ Other authors have noted a perceived improvement in skin

texture and tone following the use of both fat augmentation (believed to be secondary to stem cells present in fat)⁹ and biostimulatory agents (believed to be secondary to increased collagen production).¹⁰

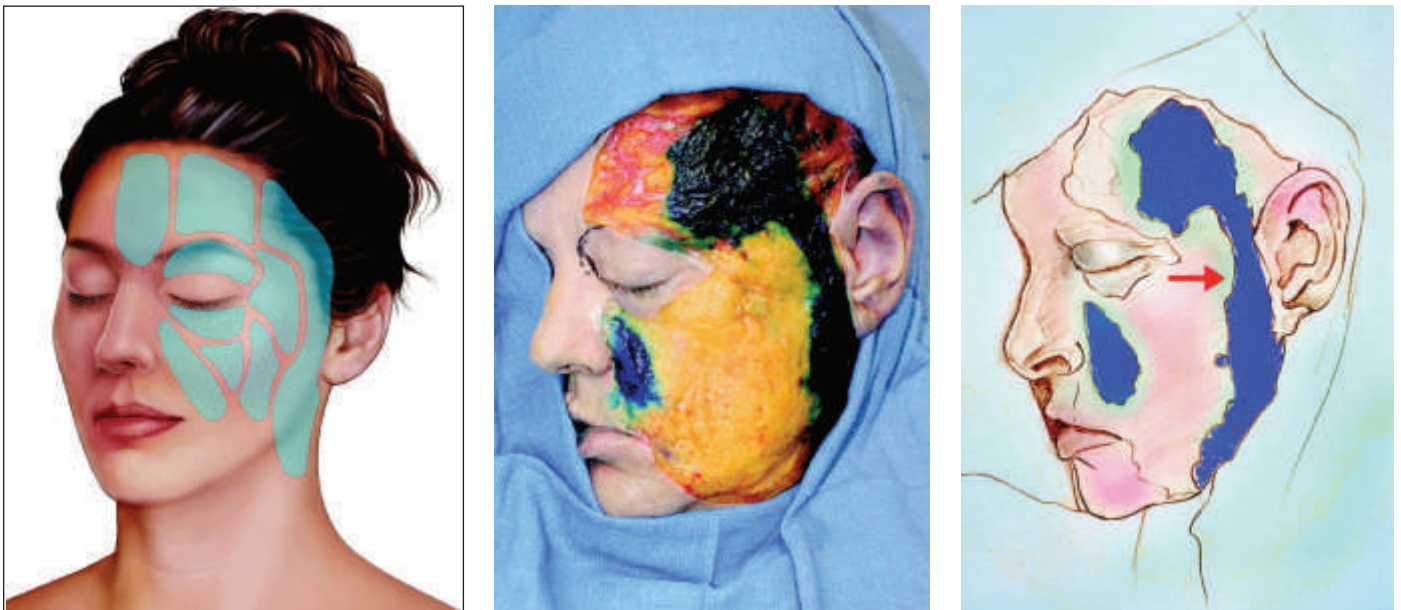Fat

The youthful face has an ample amount of volume evenly distributed, which displays a smooth transition from one area to another and confers a well-rounded 3-D topography delineated by a series of arcs and convexities.¹¹ Viewed frontally, the primary arc of the jaw line, convexities of the temples, and the smaller secondary arcs of the lips are evident.¹¹ In profile, the lateral cheek projection (the ogee curve) extending as an unbroken convex line from the lower eyelid to the cheek, the arc of the jaw line, and the arc of the forehead are the most definitive features of youth.¹²

Facial aging is associated with the loss of soft tissue fullness in the periorbital, forehead, glabellar, temporal, malar and buccal cheek perioral areas, and accumulation of fat in the infra-orbital fat pouches, nasolabial and labiomental folds, jowls, and submental areas. In addition to the redistribution of facial fat and concomitant loss of surrounding fullness, the fat pockets become more discernible as separate entities, as do many of the underlying facial structures (ie, submaxillary glands and the bony protuberances).^{11,13} Malar fat seems to slide forward and down to bulge against the nasolabial crease, and preauricular and buccal fat seem to slide forward and down to create a jowl, disrupting the defining arcs and convexities of youth. This fat appears to accumulate around the peripheral insertion of the orbicularis oris muscle into the overlying skin.

Rohrich and Pessa recently examined the anatomy of subcutaneous fat in hemifacial dissections of 30 cadavers of

Figure 1. Injection of methylene blue dye into the forehead results in a specific and reproducible pattern of staining of facial fat, demonstrating that facial fat is partitioned in discrete compartments. Adapted with permission from Rohrich RJ, Pessa J. *Plast Reconstr Surg*. 2007;119(7):2219-2227.¹⁴



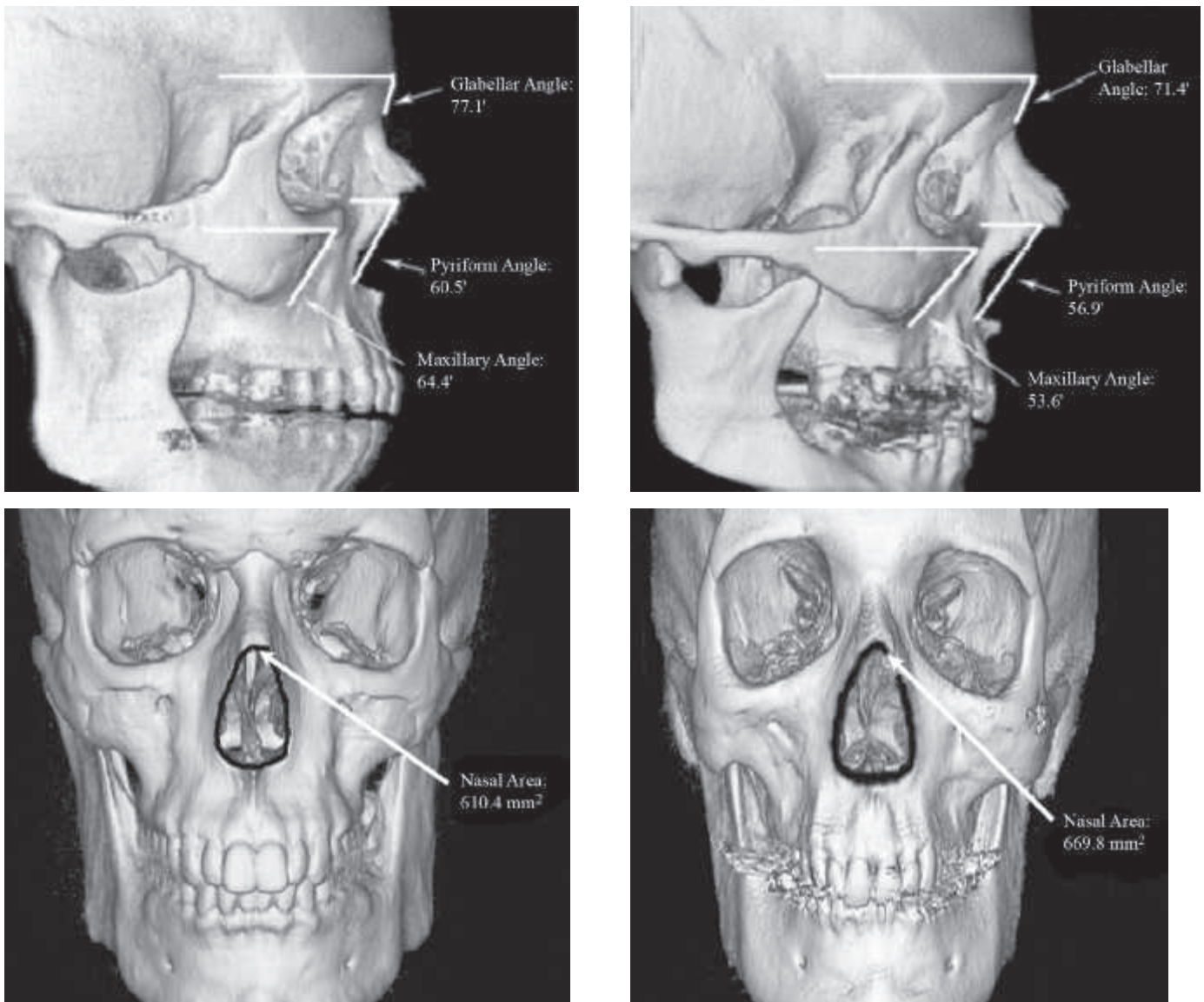
men and women aged 47 to 92 years.¹⁴ Subcutaneous injection of methylene blue dye resulted in sequestering of the dye in specific areas, demonstrating that subcutaneous fat is partitioned in discrete compartments (Figure 1).¹⁴ The authors added that each of these compartments can age independently, and a malpositioning of one compartment may lead to a cascade of changes in others. For example, the loss of volume in the deep midfacial fat would decrease support for the medial cheek compartment, resulting in a diminished midface projection and an unmasking of the nasolabial fold and malar mound. The resulting negative vector would then allow excess traction to be placed on the lower eyelid, leading to scleral show.¹⁴ To support this theory, they note that medial cheek elevation improves a prolonged “snap test,” a rapid return to baseline of lower eyelid skin after pinching,

which may indicate that lid laxity itself may play a minimal role in what is encountered clinically. Subcutaneous fat malposition and atrophy simply place downward traction on the lower lid and distort its position.¹⁴ The interdependency of age-related changes to specific facial features, such as these changes in fat and skin laxity, were also described by Goldberg et al in their study of 114 consecutive cases of “eyelid bags.”¹⁵ Just as volume loss may lead to undesirable changes elsewhere, the replacement of volume in one area may possibly lead to desirable changes in another area.

Muscle

For many years, the prevailing theory attributed to facial aging was the relaxation of muscles, and procedures were suggested to shorten or tighten them (eg, orbicularis oculi and

Figure 2. CT scan of a young (left) and old (right) female subject showing age-related decreases in mean angular measurements of the glabellar, pyriform, and maxillary angles. Also note the reduction in maxillary and mandibular height. Reprinted with permission from Shaw RB Jr, Kahn D. *Plast Reconstr Surg.* 2007;119:675-681.²⁴



zygomatic muscles) in order to rejuvenate the face.^{9,16} One flaw in this theory has been its inability to account for the fact that facial nerve paralysis results in a softening of the nasolabial, glabellar, periorbital, and labiomandibular creases. The theory is also being questioned because botulinum toxin improves the appearance of wrinkles and platysmal bands by increasing, not decreasing, their laxity.⁹ One recent study utilizing magnetic resonance imaging (MRI) found no difference in overall muscular thickness, length, or volume between subjects aged >59 years and those aged between 16 and 30 years.¹⁷ Le Louarn and colleagues used MRI to examine contrasts in the contour of facial muscles and the associated deep and superficial fat pads in persons of different ages,¹⁸ and they believe the arcs and convexities of the youthful face are secondary to both fat and muscle (ie, the position of the fat determines the shape and subsequent action of the muscle). Results from their MRI data show that the facial mimetic muscles in youth have a curvilinear contour, and thus present an anterior surface convexity, due to the presence of underlying deep fat pads. The authors theorize that this shape dictates both the direction and amplitude of muscle contractions characteristic of youthful facial expression.¹⁸ With age, these muscles, as seen in MRI, gradually straighten and shorten. The authors suggest that repeated muscle contractions in the face might over time expel fat from these deep compartments below muscle to compartments overlaying muscle tissue, which in turn leads to a straightening and shortening of the muscle along with an increase in its resting tone with aging.¹⁸ These conclusions are also consistent with the general concept that changes in individual tissues are interdependent; the alteration of one type of tissue—such as skin, muscle, or fat—contributes to changes in other tissues and leads to changes in an individual's overall facial appearance as he or she ages.

Bone

Much of the available data on craniofacial aging has been published in the forensic literature.^{19,20} An extensive, up-to-date review of the literature on the aging adult skull and face, including major contributions of the last 20 years, was recently published by Albert et al of the Departments of Anthropology and Computer Science at the University of North Carolina.²¹ The authors conclude that although there are particular biologic or environmental factors that can expedite or delay the aging process, there are indeed, "certain noticeable, agreed upon skeletal and soft tissue age-related changes in the shape, size, and configuration of individuals over the course of the adult lifespan."²¹ Doual et al found in their study with subjects ranging in age from 21 to 101 years that the most profound bony age-related morphologic modifications in the appearance of the head, face, and neck become evident around 50 years of age in both genders.²² Women exhibited greater changes and the authors suggest this is due to the effects of menopause, although they offer no further explanation. In their review article, Kloss and Gassner theorized that this may be explained by a rapid decrease in bone mass, which ensues during the first decade of menopause and places women at greater risk of bone loss, including mandibular and maxillary bone loss.²³ The authors note that aging of the craniofacial skeleton may be due

to a change in the relative dynamics of bone expansion and bone resorption.²³ These changes are greatly accelerated following tooth loss and can be devastating in elderly, edentulous patients. Oral and intravenous bisphosphonate therapy (which alters osteoclast function to prevent bone loss), and newer biologic drugs such as recombinant human parathyroid hormone (which stimulates osteoblastogenesis and inhibits osteoblast apoptosis) are currently available treatment options for osteoporosis. Additional definitive literature could not be found on the changes osteoporosis treatments may have on craniofacial bone.

The changes in craniofacial skeleton volume are profound. Shaw et al used computed tomography (CT) scans to look at the facial bone of 60 patients (30 women, 30 men) in each of 3 age categories (young: 25 to 44 years; middle: 45 to 64 years; and old: ≥ 65 years), concluding that the bony elements of the face change dramatically with age (Figure 2).²⁴ The glabellar angle in both male and female subjects showed a significant decrease with increasing age, and there was a significant orbital expansion noted superiomedially and inferiolaterally. The aging maxilla and mandible showed striking volume changes and the pyriform aperture was noted to enlarge significantly from the young to middle-aged group in both sexes.²⁴ These findings corroborate with those of Pessa et al, whose work during the past decade has also implicated bony remodeling as a key factor in the pathogenesis of facial aging.²⁵ Using CT imaging and 3-D stereolithography, Pessa et al demonstrated a posterior-inferior rotation of the facial skeleton toward the cranial base with the progression of age, as was first theorized by Lambros.²⁵ This can be conceptualized as a slight clockwise rotation of the maxilla with the face in profile. This maxillary retrusion is thought to further undermine midfacial support and projection, including those of the inferior orbital rim, and contribute to malposition of the lower eyelid resulting in lateral bowing and scleral show. As mentioned above, Goldberg et al have also implicated decreased midfacial support in the pathogenesis of eyelid bags.¹⁵ Levine et al argued that the maxillary wall moves counter-clockwise (anteriorly) with age, based on results of longitudinal cephalometric analysis of midface changes in subjects up to 83 years of age.²⁶ These authors argue that a clockwise rotation would lead to compression of the upper airway and sleep apnea. Results from more recent studies by Mendelson et al, however, also indicate retrusion of the maxillary wall with aging.²⁷ While this debate will be resolved with time, what is certain now is that craniofacial remodeling results in a profound loss of underlying surface support for overlying soft tissue.

Craniofacial Aging and Perioral Proportions

In a retrospective analysis of CT data, Pessa and colleagues examined the ratio of the oblique height of the medial orbit to the height of the medial maxilla in infants (age 1-12 months; $n=5$), youthful subjects (age 15-24 years; $n=13$), and older subjects (age 53-76 years; $n=12$).²⁸ Results showed that this ratio increases from an average of 0.48 in infants to 0.78 in young adults and subsequently decreases significantly to 0.68 in older individuals ($P<.0001$ between all 3 groups) (Figure 3). The investigators also theorized that if the older

group were followed longer, the ratio would likely continue to approach the ratio of 0.48 observed in the infant group.²⁸ The authors note that this shift of skeletal proportions in the midface following early adulthood leads to a decrease of the available space for facial soft tissue support in older individuals, and, as a result, soft tissues in this region may reposition in an accordion-like manner, referred to as a “concertina” effect.²⁸ The concertina effect may explain in part why infants look somewhat like aged persons in the soft contours of the midface. Like aged persons, infants have prominent nasolabial and nasojugal folds and creases as well as soft tissue positioned lower in the midface (jowls). In addition to these similarities in soft tissue position, there is also a striking similarity in the ratio of the upper lip to the chin (1:1) in the aged and infant face. This is in contrast to the 1/3:2/3 ratio seen in the young face (Figure 3). It was precisely these changes in the perioral proportions of the aging face, seemingly due to bone loss with soft tissue repositioning, that prompted the examination as to whether this ratio could be improved with bony augmentation, specifically, bony augmentation with an injectable agent.

Facial Balance, Proportions, and Symmetry

Balance and proportions of the face have been measured over time in almost every conceivable way³; however, some simple measurements that are well-accepted standards (Figure 4) allow us to compare changes in these areas between young and aged faces.²⁹ As the face ages, one can see predictable changes in its proportions. Looking at the face in vertical fifths and horizontal thirds, we see the change from the so-

called “triangle of youth” to the “pyramid of age” as the forehead narrows (due to temporal atrophy) and elongates (due to loss of underlying support, causing the brows to droop as the hairline recedes), and as the lower face widens (as jowls form) and shortens (as bone is remodeled in the maxilla and mandible). Focusing on the perioral region, the young face shows a 1/3:2/3 ratio of upper lip to chin, the so-called “golden mean.”^{30,31} With age, this ratio approaches 1:1. This perioral ratio change is clearly illustrated in Figure 5. Both the male and female patients illustrated here are from the third, fifth, and seventh decade of life. The male patients all have severe disease related lipoatrophy, allowing for comparison with the nonlipoatrophic female patients.

Finally, most faces exhibit some bilateral asymmetry, which may reflect a developmental instability, accounting for its importance in the assessment of attractiveness.⁷ Mild asymmetry is easily addressed with fillers and botulinum toxin. Higher degrees of asymmetry may be only partially corrected with these measures. This may be, in part, because the volume loss in more severe cases involves both soft tissue and bone.

Supraperiosteal PLLA for Perioral Rejuvenation

Volume loss, contours, and midface projection and proportions have been addressed successfully with both soft tissue augmentation and bony implants.^{9,32,33} Treatment of soft tissue alone does not effectively address the perioral ratio change seen with aging (Figure 6). Surgical procedures removing tissue at either the superior or inferior pole of the cutaneous upper lip have been used to address this ratio³⁴; however, many patients find the resultant scars objectionable.

Figure 3. The ratio between oblique height of the medial orbit to the height of the medial maxilla increases from infancy to young adulthood and then decreases with age. Adapted with permission from Pessa JE, Zadoo VP, Yuan C, et al. *Plast Reconstr Surg*.1999;103:635-644.²⁸

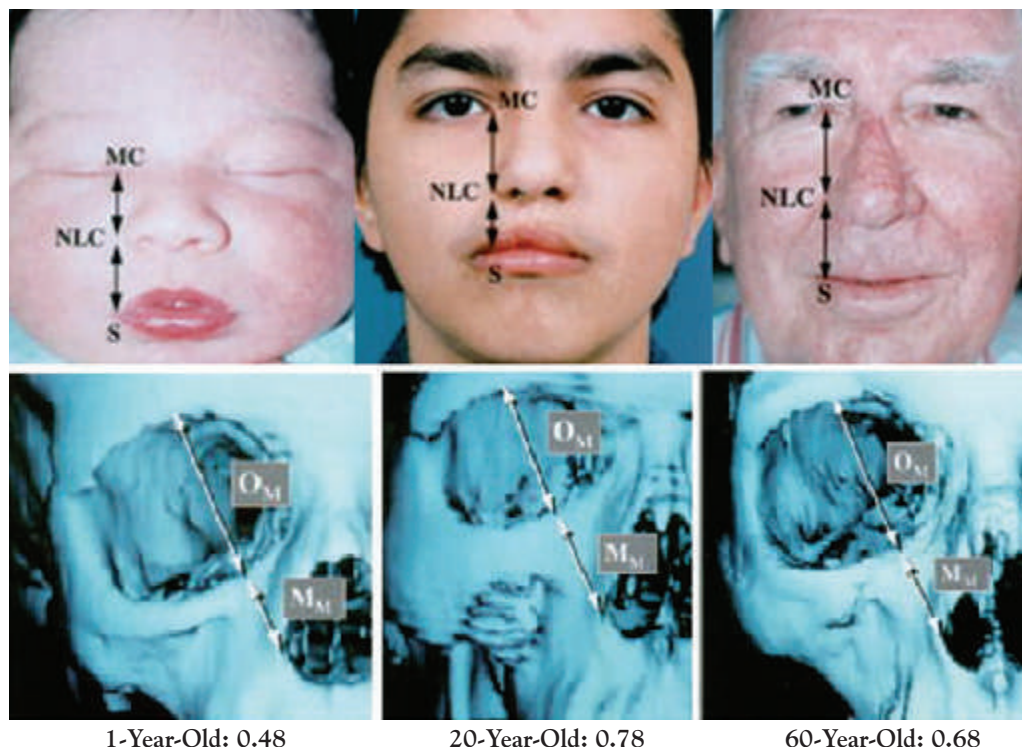
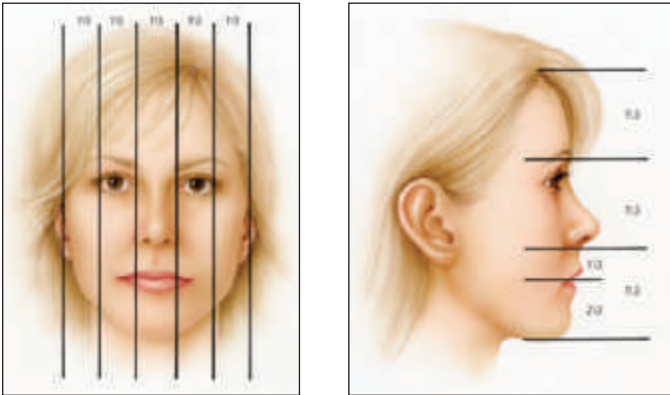

Figure 4. Horizontal and vertical facial proportions. Adapted with permission from Azizzadeh B, Murphy M, Johnson CM. In: *Master Techniques in Facial Rejuvenation*. Elsevier, 2007.²⁹

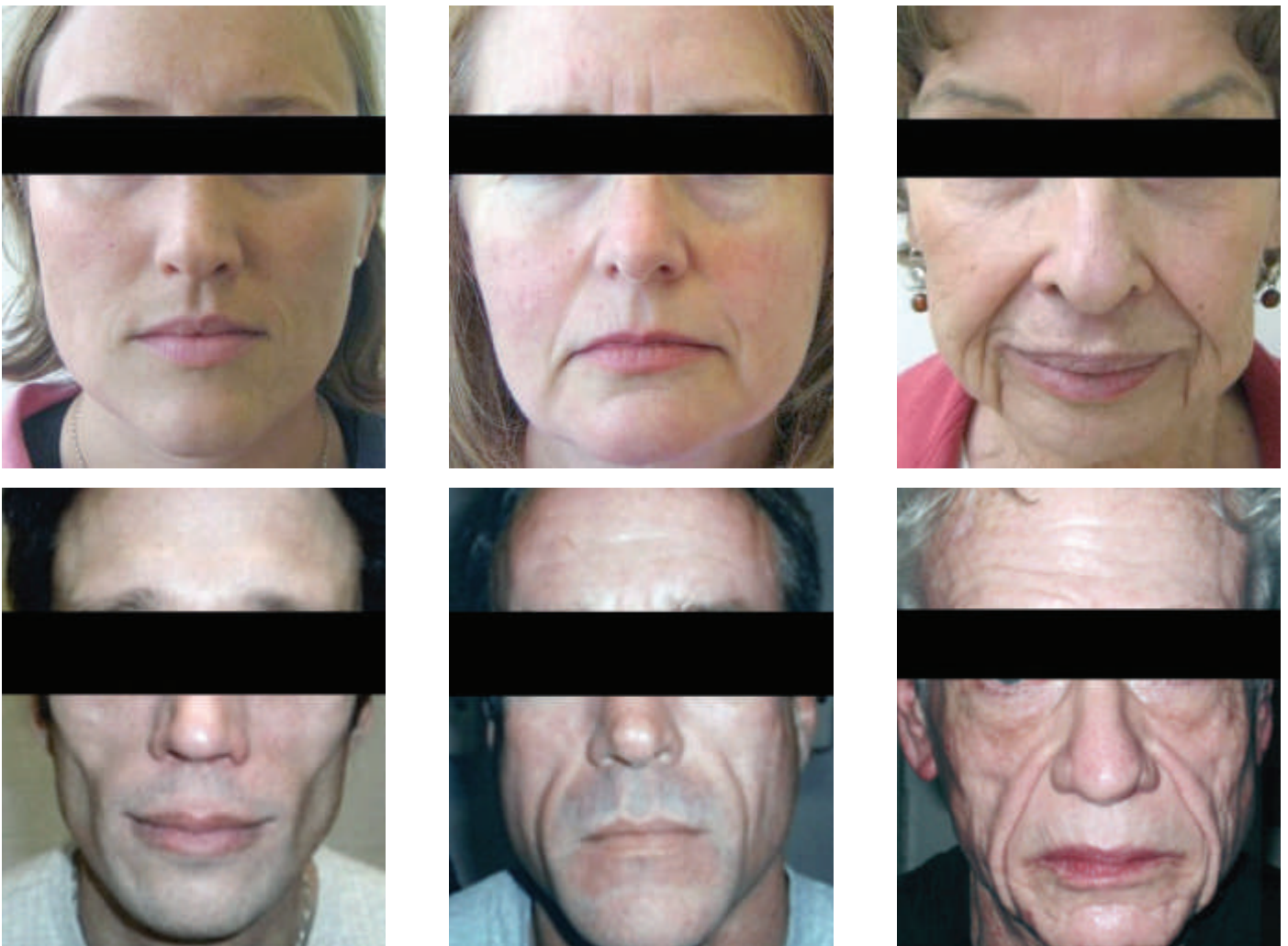

The change in perioral proportions in the aging face, perhaps due to bone loss and soft tissue repositioning, led to speculation as to whether this ratio could be improved with non-surgical bony augmentation. Several cases of patients receiving treatment in both the soft tissue and in the supraperiosteal area to address volume, contours, and midface descent and projection, as well as proportions of the perioral region of the face are presented.

Factors in Product Choice

The recent approval of hyaluronic acid derivatives (Restylane[®], Perlane[®], and Juvéderm[®]), calcium hydroxylapatite (Radiesse[®]), and PLLA (Sculptra[®]) have enhanced the ability to provide correction of the volume deficits encountered with aging. Although all these products have relatively similar favorable safety and tolerability profiles, they have very different modes of operation. Fillers such as hyaluronic acid may be used in any volume desired in any one session. Biocompatible synthetic agents such as calcium hydroxylapatite and PLLA may require multiple sessions. With

Figure 5. Patients in their 3rd, 5th, and 7th decade of life illustrating volume and proportional changes. The male patients shown have severe HIV-related facial lipoatrophy allowing visualization of the bony changes without fat accumulation.



biocompatible synthetic agents, the amount of product used at any one session is determined by the surface area to be treated per session. Total volumetric correction is determined by the number of treatments. With multiple treatments, these agents can replace the same significant volume loss as fat augmentation. The hyaluronic acids and calcium hydroxylapatite in a gel carrier are characterized by stiffness and structure, and are more akin to bulking agents.³⁵ Poly-L-lactic acid has a very low viscosity and is used as a layering agent.^{33,36} It should be noted that vascular compromise with bulking agents (ie, hyaluronic acid) in the distribution of the angular artery has been reported (Figure 7).³⁷ Although hyaluronidase has been used successfully to dissolve hyaluronic acid products, no similar treatment is available should an ischemic event occur with a calcium hydroxylapatite product. In addition, reflux prior to injection (to prevent intravascular injection) is technically difficult with calcium hydroxylapatite products. The risk of intravascular PLLA injection in these case studies was avoided by performing a reflux maneuver after insertion of the needle and

prior to each injection. In addition, PLLA has a low viscosity, which minimized the risk of vascular compromise from swelling and compression when used in areas with poor collateral flow, such as around the pyriform aperture.

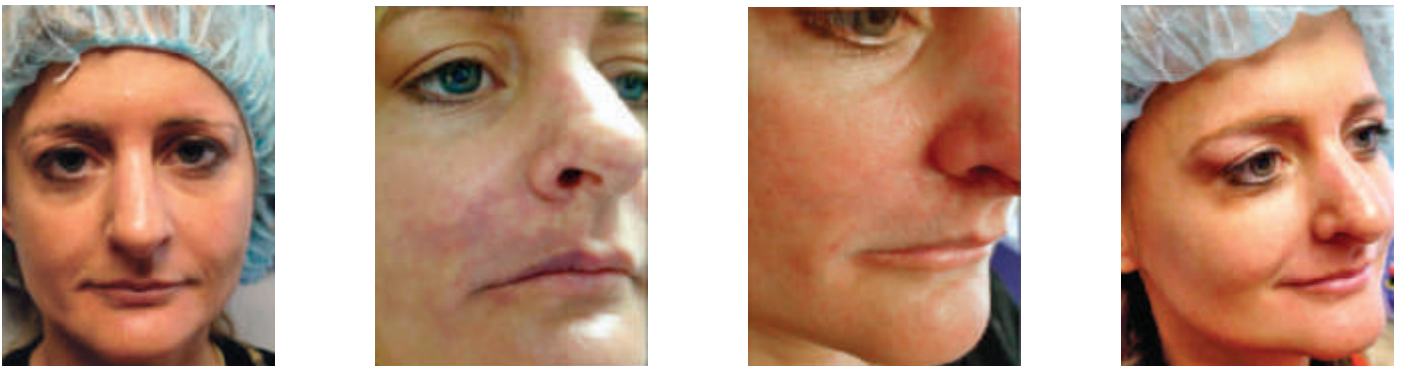
Case Studies

A total of 4 cases are presented with patients ranging in age from 37 to 61 years. All patients show varying degrees of changes in individual tissue layers resulting in an overall appearance of global volume loss. While the changes in all patients follow a predictable pattern, the degree of change is variable between individuals as is the degree of change between different tissue layers in a single individual. All patients show some loss of thickness and elasticity in the skin, affecting its ability to fully accommodate the volume loss in underlying tissues. Each case study shows some degree of fat loss and a repositioning of the youthful arcs and convexities that reflect light to flattened or even concave areas, resulting in interrupted light and intervening shadows. All cases show varying degrees of skeletal remodeling, resulting in de-

Figure 6. Soft tissue treatment addresses contour deficiencies, but not perioral proportions.

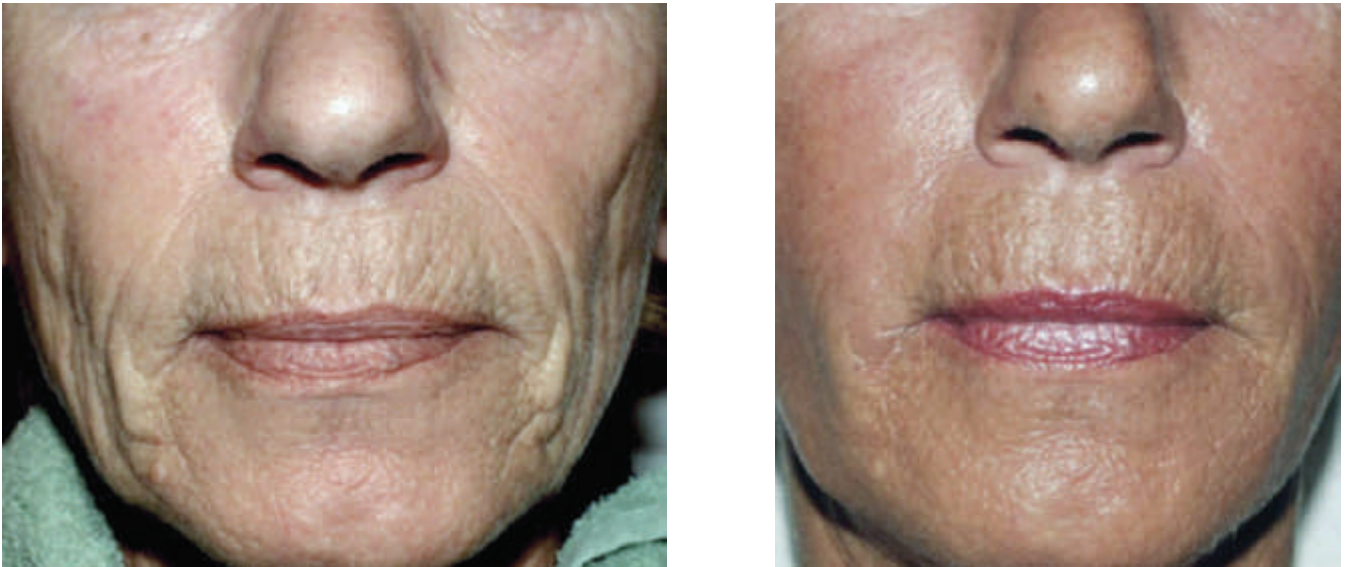

Figure 7. Vascular compromise noted 6 hours after injection of hyaluronic acid successfully treated with hyaluronidase. Reprinted with permission from Hirsch RJ, Cohen JL, Carruthers JD. *J Derm Surg.* 2007;33:357-360.³⁷



creased surface area of bony support for overlying soft tissue. The descent of soft tissue results in eye bags, nasolabial folds, and jowls, interrupting the smooth transition from one area to another that defines youthful topography. The patients represent varying stages of transition from the triangle of youth (see Figure 4; a width of "5 eyes across" at the temples, with a tapering to a longer and narrower lower face), to the pyramid of age (with a narrowing of the upper third of the face to less than 5 eyes across accompanied by a shortening and widening of the lower third of the face as bone remodels and fat accumulates along the jaw, disrupting the smooth arc of the youthful jawline). Skeletal loss adjacent to fat accumulation (canine fossa/nasolabial fold, prejowl mandibular loss/jowl) alter the facial surface; smooth transitions now become well defined, and the youthful perioral lip:chin ratio of 1/3:2/3 approaches 1:1.

Four patients (Figures 8 to 11) were treated using PLLA³⁸ diluted with 5 cc of sterile water for injection and left to hydrate overnight. In addition, 1 to 2 cc of 1% lidocaine without epinephrine was added immediately prior to injection. Treatments were administered with a 26-gauge needle and 3-cc syringe. It should be noted that this reconstitution procedure differs slightly from the manufacturer's recommended dilution of PLLA (3 to 5 mL sterile water for injection, allowed to stand for at least 2 hours, and then agitated prior to use).³⁸ In addition, the supraperiosteal injections performed also lie outside the manufacturer's recommendation of injecting PLLA into the deep dermis or subcutaneous layers.³⁸

The patients received soft tissue injections of PLLA into the midface deep dermal/subcutaneous plane, both superior and inferior to the malar fat, and in the mental crease and lateral chin (between the depressor anguli oris and the mentalis muscle) to revolumize soft tissue. Provocation of tissue weakness in these areas helped direct placement. The amount of product used at any one session was based on the surface area to be treated. Final volumetric correction was addressed by increasing the number of sessions and not by increasing the amount of product per session.

Supraperiosteal injections in the maxillary area were placed around the medial aspect of the zygoma, around the pyriform aperture, and in the canine fossa, roughly simulating the area covered by the porous ethylene implants pictured in Figure 12. Likewise, the supraperiosteal mandibular injections were placed over the bone in an area similar to that pictured in the same figure, in an effort to replace the volume lost as the anterior mandible shortens and flattens, and the anterior mandibular ridge is effaced.

Through this combined approach, an improvement was observed in both the volume and position of soft tissue and in the proportions of the face, in particular, in the perioral area. Note that in all cases the cutaneous portion of the upper lip appears shortened and more convex and the nasal tip is elevated. Although none of these patients received filler in the lips, all display some degree of improvement in this area (from flatter and wider to shorter and more convex) with slightly more mucosal show. In addition, all showed a length-

Figure 8. 37-year-old woman: a) no previous dermal filler treatments; b) PLLA 2 vials per treatment; 3 treatments/4-week intervals.

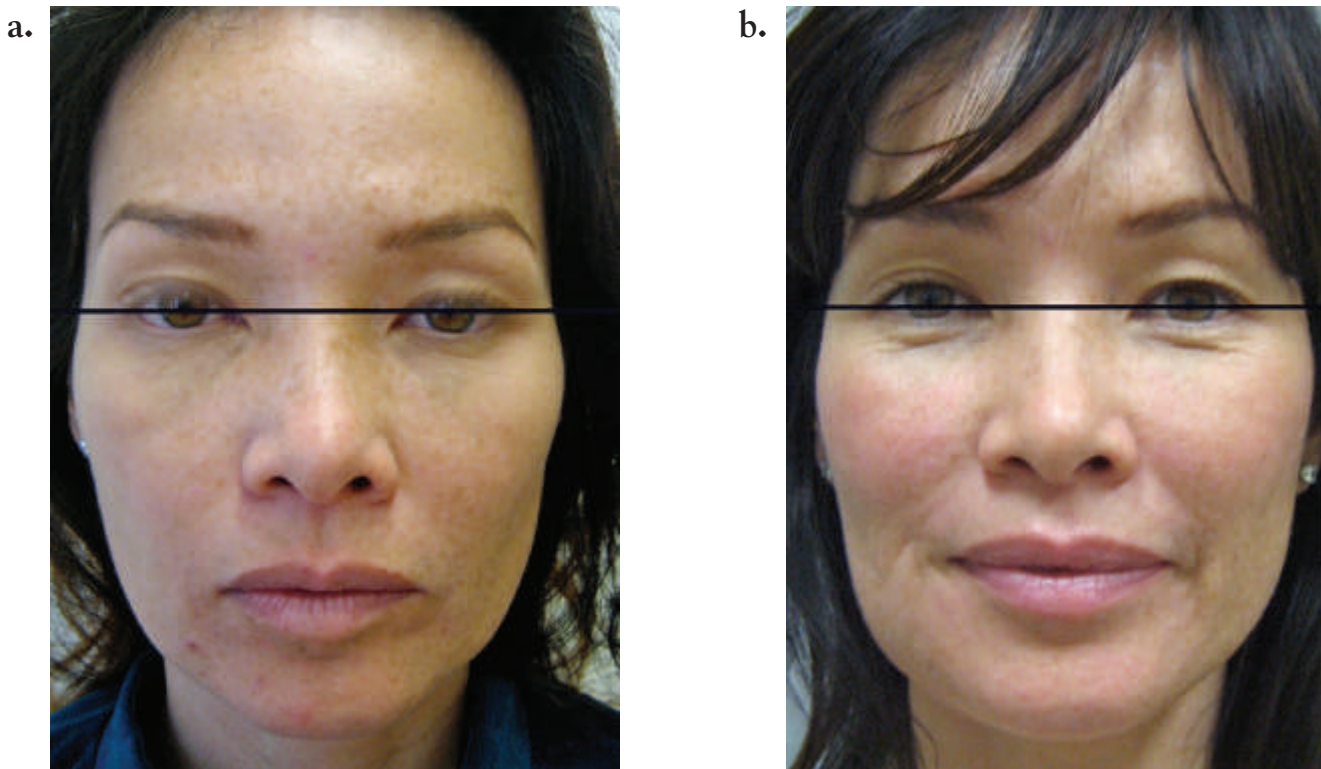
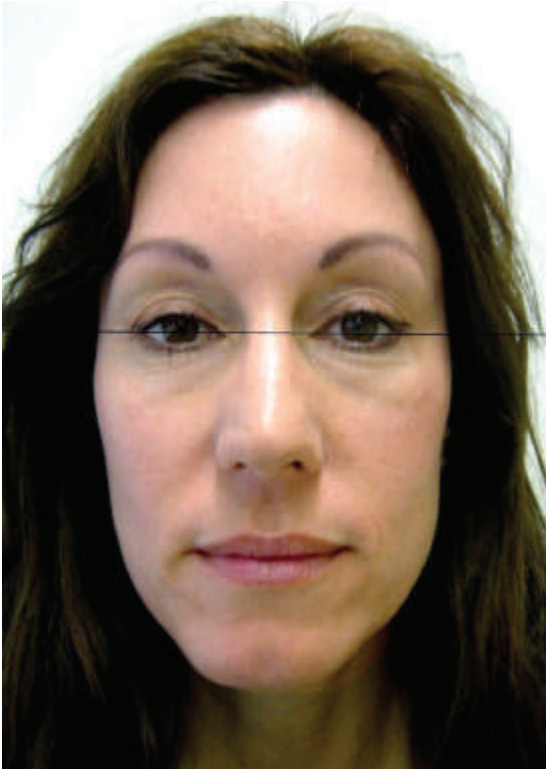
Figure 9. 46-year-old woman: a) no previous treatments; b) PLLA 2 vials per treatment; 3 treatments/4-week intervals.

a.



b.

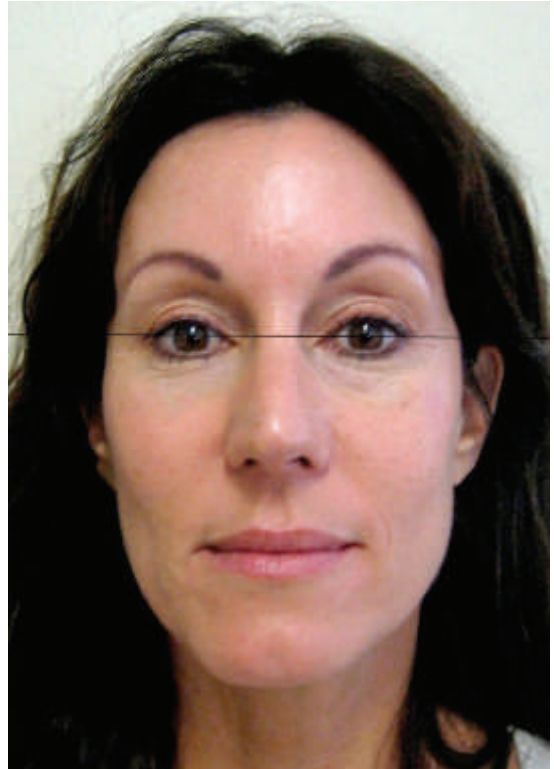
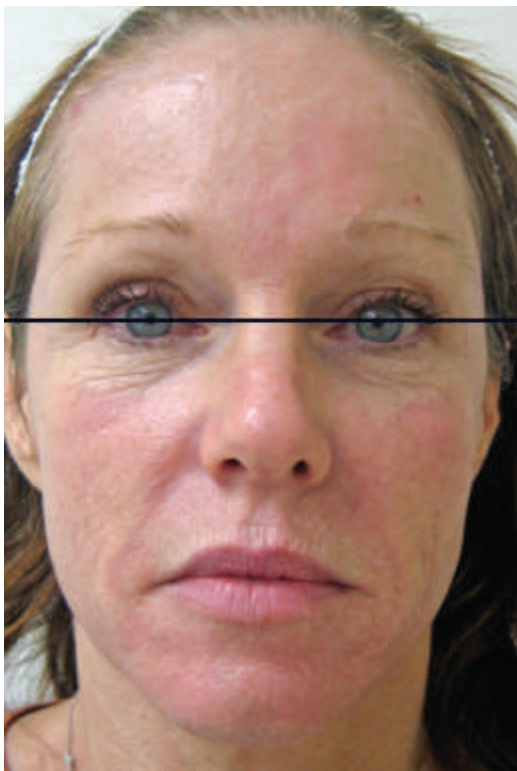
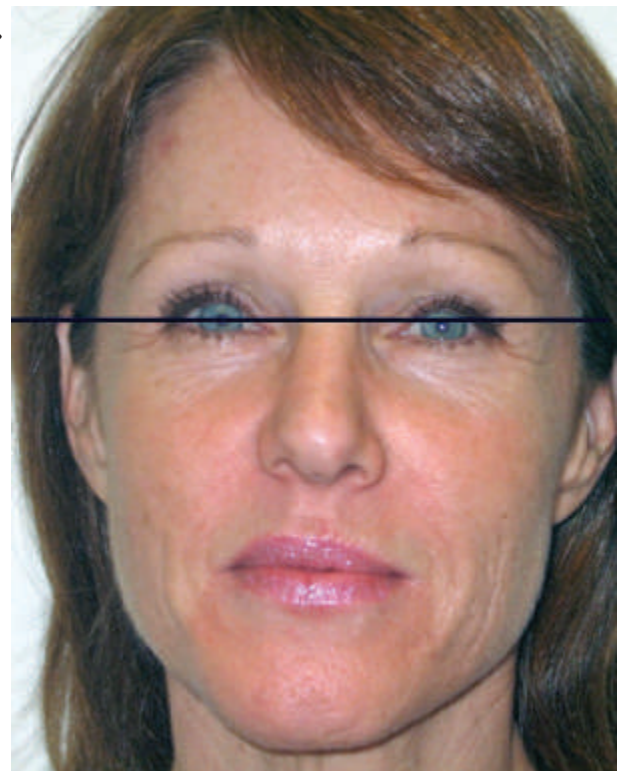Figure 10. 50-year-old woman: a) no previous treatments; b) PLLA 2 vials per treatment; 2 treatments/4-week intervals.

a.



b.



ening of their chin after treatment. In concert, these changes contribute to a restoration in the perioral ratio of the lower third of the face toward the 1/3:2/3 ratio of youth. All patients showed improvement in eyelid bags (presumably secondary to an increase in midfacial support) and bilateral symmetry, most notable in case 4 (Figure 11). All noted a subjective improvement in the quality of their skin.

Photographs were taken 6 to 12 months after each patient's final treatment. Although all cases showed some improvement in temporal volume, upon further review, we noted the patients would have most likely benefited from an increased treatment in the temporal region to more closely approximate the youthful width of 5 eyes across in this area.

Discussion and Conclusion

It is by now a well-accepted and agreed-upon fact that mastery of volume replacement is essential to the practice of facial rejuvenation. Learning more about where and how that volume is lost, and where to best replace it, will enhance our ability to obtain natural-looking results. Treatment of the perioral area is challenging. This article presents the experiences with a novel, long-lasting injectable device used to replace volume loss both in soft tissue and over bone to improve facial contours and proportions.

Although a unique use of PLLA for facial aging is described in this article, the use of the device for volume restoration is not new.³⁹ Poly-L-lactic acid is a biodegradable, biocompat-

Figure 11. 61-year-old woman: a) no previous treatments; b) PLLA 2 vials per treatment; 4 treatments/4-week intervals.

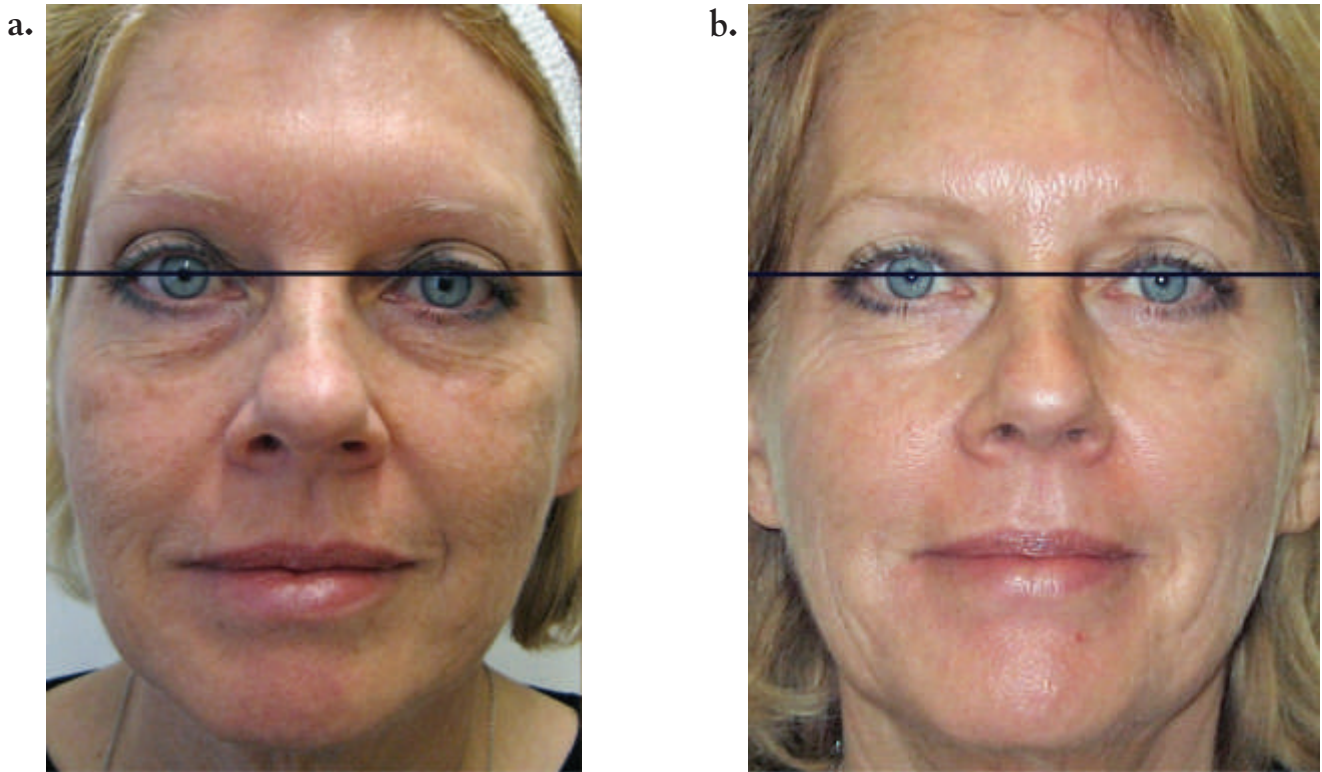
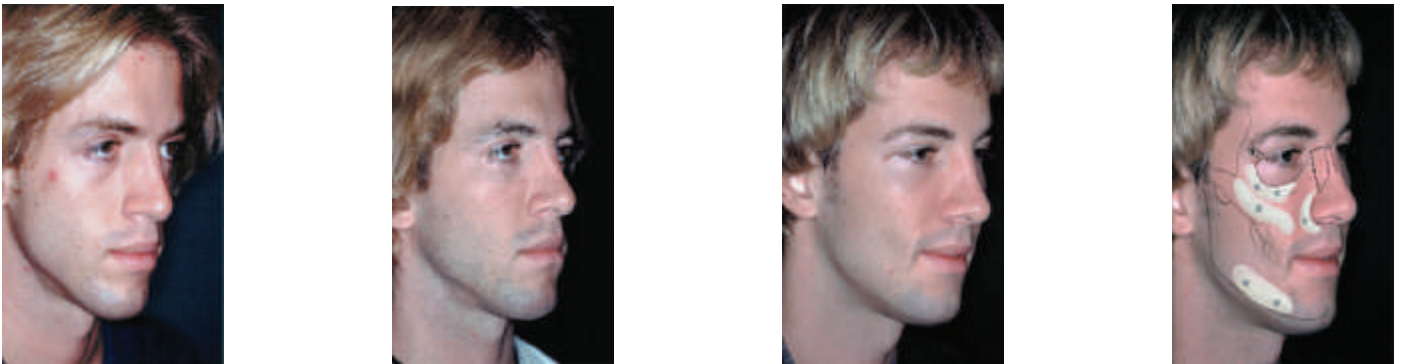

Figure 12. Changes to the facial contours of a 24-year-old male patient following implantation of porous polyethylene. Reprinted with permission from Yaremchuk MJ. *Plast Reconstr Surg.* 2003;111:1818-1827.³²



ible, immunologically inert, synthetic polymer device derived from the alpha hydroxy acid family that has been shown to be effective for correcting volume deficits since 1999.^{33,36,40-42} Early studies using PLLA to treat HIV-related facial lipoatrophy reported the occurrence of papules and nodules ranging from 13% to 52% of subjects,^{43,44} but frequency has diminished dramatically with experience. The occurrence of nodules and papules is a possibility with all agents, such as the hyaluronic acid derivatives, collagen, and even autologous fat.⁴⁵ Experience with PLLA has helped determine proper dilution, hydration time, and placement, as well as the fact that posttreatment massage and sufficient time between treatments are important to ensure optimal outcomes with a biocompatible synthetic agent. The most common adverse events with the use of dermal fillers, regardless of class, are related to the injection site and include bruising, swelling, and pain.^{43,44,46,47} In addition to this information, it is important to receive proper training in the technique prior to treating patients.

As demonstrated in these cases, the use of PLLA in a supraperiosteal location as an injectable implant restored a youthful perioral ratio in patients, providing a very natural-looking and desirable result. This proportional change had not been achieved previously with soft tissue augmentation alone. Although effective for filling wrinkles and restoring lost volume, the hyaluronic acids and calcium hydroxylapatite are less suitable for the purpose of restoring skeletal structure described here due to their bulky nature. Although not currently recommended by the manufacturer for use in skeletal restoration, PLLA has a viscosity that permits supraperiosteal injections which can restore the lost skeletal structure that accompanies age without the potential for vascular compromise. Further research will ultimately be the arbiter of the significance of skeletal remodeling in the deflation of the face with age and provide additional clues as to how best to restore youthful features to the aging face.

Acknowledgments

Editorial support for this article was provided by Dermik Laboratories, a business of sanofi-aventis U.S. LLC. The opinions expressed in this article are those of the authors. The authors received no honoraria or other form of financial support related to the development of this manuscript.

References

- Langlois JH, Kalakanis L, Rubenstein AJ, et al. Maxims or myths of beauty? A meta-analytic and theoretical review. *Psychol Bull.* 2000;126:390-423.
- Olson IR, Marshuetz C. Facial attractiveness is appraised in a glance. *Emotion.* 2005;5:498-502.
- Bashour M. History and current concepts in the analysis of facial attractiveness. *Plast Reconstr Surg.* 2006;118:741-756.
- American Society for Aesthetic Plastic Surgery. 2005 Cosmetic Surgery National Data Bank Statistics. 1-20. 2007.
- Tan CY, Statham B, Marks R, Payne PA. Skin thickness measurement by pulsed ultrasound: its reproducibility, validation and variability. *Br J Dermatol.* 1982;106:657-667.
- Varani J, Dame MK, Rittie L, et al. Decreased collagen production in chronologically aged skin: roles of age-dependent alteration in fibroblast function and defective mechanical stimulation. *Am J Pathol.* 2006;168:1861-1868.
- Friedman O. Changes associated with the aging face. *Facial Plast Surg Clin North Am.* 2005;13:371-380.
- Sadick N. The science of next generation anti-aging cosmeceuticals. *J Drugs Dermatol.* 2007;6:S1.
- Donath AS, Glasgold RA, Glasgold MJ. Volume loss versus gravity: new concepts in facial aging. *Curr Opin Otolaryngol Head Neck Surg.* 2007;15:238-243.
- Fitzgerald R. Utilization of treatment options for facial lipoatrophy. *Cosmetic Dermatology.* 2006;19(suppl):12-20.
- Donofrio LM. Fat distribution: a morphologic study of the aging face. *Dermatol Surg.* 2000;26:1107-1112.
- Coleman SR, Grover R. The anatomy of the aging face: Volume loss and changes in 3-dimensional topography. *Aesthetic Plast Surg.* 2006;26:S4-S9.
- Ascher B, Coleman S, Alster T, et al. Full scope of effect of facial lipoatrophy: a framework of disease understanding. *Dermatol Surg.* 2006;32:1058-1069.
- Rohrich RJ, Pessa JE. The fat compartments of the face: anatomy and clinical implications for cosmetic surgery. *Plast Reconstr Surg.* 2007;119:2219-2227.
- Goldberg RA, McCann JD, Fiaschetti D, Ben Simon GJ. What causes eyelid bags? Analysis of 114 consecutive patients. *Plast Reconstr Surg.* 2005;115:1395-1402.
- Furnas DW. Festoons, mounds, and bags of the eyelids and cheek. *Clin Plast Surg.* 1993;20:367-385.
- Gosain AK, Klein MH, Sudhakar PV, Prost RW. A volumetric analysis of soft-tissue changes in the aging midface using high-resolution MRI: implications for facial rejuvenation. *Plast Reconstr Surg.* 2005;115:1143-1152.
- Le Louarn CL, Buthiau D, Buis J. Structural aging: the facial re-curve concept. *Aesthetic Plast Surg.* 2007;31:213-218.
- Farkas LG, Eiben OG, Sivkov S, et al. Anthropometric measurements of the facial framework in adulthood: age-related changes in eight age categories in 600 healthy white North Americans of European ancestry from 16 to 90 years of age. *J Craniofac Surg.* 2004;15:288-298.
- Behrents RG. The biological basis for understanding craniofacial growth during adulthood. *Prog Clin Biol Res.* 1985;187:307-319.
- Albert AM, Ricanek K Jr, Patterson E. A review of the literature on the aging adult skull and face: implications for forensic science research and applications. *Forensic Sci Int.* 2007;172:1-9.
- Doual JM, Ferri J, Laude M. The influence of senescence on craniofacial and cervical morphology in humans. *Surg Radiol Anat.* 1997;19:175-183.
- Kloss FR, Gassner R. Bone and aging: effects on the maxillofacial skeleton. *Exp Gerontol.* 2006;41:123-129.
- Shaw RB, Jr, Kahn DM. Aging of the midface bony elements: a three-dimensional computed tomographic study. *Plast Reconstr Surg.* 2007;119:675-681.
- Pessa JE. An algorithm of facial aging: verification of Lambros's theory by three-dimensional stereolithography, with reference to the pathogenesis of midfacial aging, scleral show, and the lateral sub-orbital trough deformity. *Plast Reconstr Surg.* 2000;106:479-488.

26. Levine RA, Garza JR, Wang PT, et al. Adult facial growth: applications to aesthetic surgery. *Aesthetic Plast Surg.* 2003;27:265-268.
27. Mendelson BC, Hartley W, Scott M, et al. Age-related changes of the orbit and midcheek and the implications for facial rejuvenation. *Aesthetic Plast Surg.* 2007;31:419-423.
28. Pessa JE, Zadoo VP, Yuan C, et al. Concertina effect and facial aging: nonlinear aspects of youthfulness and skeletal remodeling, and why, perhaps, infants have jowls. *Plast Reconstr Surg.* 1999;103:635-644.
29. Azizzadeh B, Murphy MR, Johnson CM. The Aging Face Consultation. In: *Master Techniques in Facial Rejuvenation.* Elsevier, 2006: 1-16.
30. Bashour M. An objective system for measuring facial attractiveness. *Plast Reconstr Surg.* 2006;118:757-774.
31. Naini FB, Moss JP, Gill DS. The enigma of facial beauty: esthetics, proportions, deformity, and controversy. *Am J Orthod Dentofacial Orthop.* 2006;130:277-282.
32. Yaremchuk MJ. Facial skeletal reconstruction using porous polyethylene implants. *Plast Reconstr Surg.* 2003;111:1818-1827.
33. Vleggaar D. Facial volumetric correction with injectable poly-L-lactic acid. *Dermatol Surg.* 2005;31:1511-1517.
34. Ali MJ, Ende K, Maas CS. Perioral rejuvenation and lip augmentation. *Facial Plast Surg Clin North Am.* 2007;15:491-500.
35. Jacovella PF, Peiretti CB, Cunille D, et al. Long-lasting results with hydroxylapatite (Radiesse) facial filler. *Plast Reconstr Surg.* 2006;118(suppl):15S-21S.
36. Lam SM, Azizzadeh B, Graivier M. Injectable poly-L-lactic acid (Sculptra): technical considerations in soft-tissue contouring. *Plast Reconstr Surg.* 2006;118(suppl):55S-63S.
37. Hirsch RJ, Cohen JL, Carruthers JD. Successful management of an unusual presentation of impending necrosis following a hyaluronic acid injection embolus and a proposed algorithm for management with hyaluronidase. *Dermatol Surg.* 2007;33:357-360.
38. Sculptra® [prescribing information]. Berwyn, PA; Dermik Laboratories; 2006.
39. Simamora P, Chern W. Poly-L-lactic acid: an overview. *J Drugs Dermatol.* 2006;5:436-440.
40. Sadick NS, Burgess C. Clinical experience of adverse outcomes associated with poly-L-lactic acid. *J Drugs Dermatol.* 2007;6(1 (suppl)):S4-S8.
41. Vleggaar D. Soft-tissue augmentation and the role of poly-L-lactic acid. *Plast Reconstr Surg.* 2006;118(suppl):46S-54S.
42. Vleggaar D, Bauer U. Facial enhancement and the European experience with Sculptra (poly-L-lactic acid). *J Drugs Dermatol.* 2004;3:542-547.
43. Valantin MA, Aubron-Olivier C, Ghosn J, et al. Polylactic acid implants (New-Fill) to correct facial lipoatrophy in HIV-infected patients: results of the open-label study VEGA. *AIDS.* 2003;17:2471-2477.
44. Mest DR, Humble G. Safety and efficacy of poly-L-lactic acid injections in persons with HIV-associated lipoatrophy: the US experience. *Dermatol Surg.* 2006;32:1336-1345.
45. Lemperle G, Rullan PP, Gauthier-Hazan N. Avoiding and treating dermal filler complications. *Plast Reconstr Surg.* 2006;118 (suppl):92S-107S.
46. Silvers SL, Eviatar JA, Echavez MI, Pappas AL. Prospective, open-label, 18-month trial of calcium hydroxylapatite (Radiesse) for facial soft-tissue augmentation in patients with human immunodeficiency virus-associated lipoatrophy: one-year durability. *Plast Reconstr Surg.* 2006;118(suppl):34S-45S.
47. Narins RS, Brandt F, Leyden J, et al. A randomized, double-blind, multicenter comparison of the efficacy and tolerability of Restylane versus Zyplast for the correction of nasolabial folds. *Dermatol Surg.* 2003;29:588-595.

ADDRESS FOR CORRESPONDENCE

Danny Vleggaar MD
Le Col, Les Escombes
26230 Roussas
France
e-mail: drdanny@vleggaar.net